



## BONE HYPERTROPHIES IN EDENTULOUS PATIENTS: FROM DIAGNOSIS TO PROSTHETIC REHABILITATION

| Kanza Mrhar<sup>1\*</sup> | Yasmina Cheikh<sup>1</sup> | Khadija El assraoui<sup>1</sup> | and | Samira Bellemkhannate<sup>1</sup> |

<sup>1</sup> Faculty of Dentistry, Hassan II University | Department of Removable Prosthodontics, | Casablanca | Morocco |

| Received August 16, 2020 |

| Accepted September , 2020 |

| Published September 30, 2020 |

| ID Article | Kanza-Ref.14-ajira160920-|

### ABSTRACT

During the clinical examination of a totally toothless patient, we can detect various osteo-mucosal abnormalities, which can compromise both prosthetic stability and aesthetics. Among these anatomical constraints are bone hypertrophies on the prosthetic bearing surface, which most often require surgery.

**Keywords:** Bone hypertrophies, torus, prosthetic space, surgical management

### 1. INTRODUCTION

Total edentulism remains a condition attributed to old age and social precariousness, despite the development and progress of conservative dentistry. Its prosthetic restoration constitutes a certain difficulty accentuated by unfavorable anatomical and physiological conditions. Indeed, there are situations where the transition to the prosthetic act cannot be made right away, hence the indication for surgery is necessary, allowing the future prosthesis to be better seated and the patient to adapt more quickly, with better aesthetic and functional performance [1, 2].

Among these anatomical constraints are hypertrophies or bone exostoses in the prosthesis support zones, which raise the following difficulties during prosthetic rehabilitation: reduction of the prosthetic space, exaggerated labio-jugal support provided by the ridge and interference with the physiological movement of the peripheral musculature [3].

These hypertrophies are benign, slow-growing, non-neoplastic bone growths with different localizations. Most of the time they are asymptomatic and are usually discovered fortuitously by a routine examination [4, 5, 6]. These excrescences are described according to their location, size or morphology. Their classification is necessary for their clinical management, whether surgical or prosthetic.

A distinction is made between the torus or tori palatins if they are located along the longitudinal crest of the hard palate, and the tori mandibularis (TM) if they are located on the lingual side of the mandible above the mylohyoid line, in the premolar canine region. And exostoses that are found in the maxillary and/or mandibular region outside the areas already mentioned. The mucosa covering these protuberances is hypovascularized and thin [6].

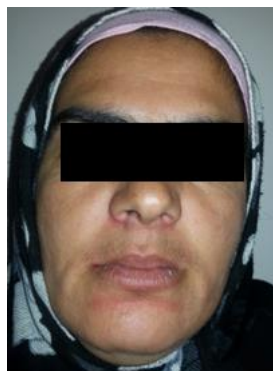Maxillary exostoses are most often located next to the molars, sometimes extending to the second premolar and, in rare cases, to the canine and incisors [7].

The morphology of the exostoses is variable, they may be smooth and continuous with the ridge, or manifest as single or multiple nodules with sometimes pointed bone projections, thus generating tension on the mucosa [8].

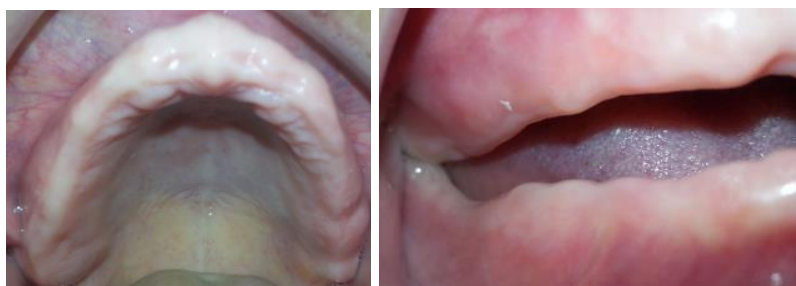### 2. CLINICAL CASE REPORT

#### 2.1 First Clinical Case

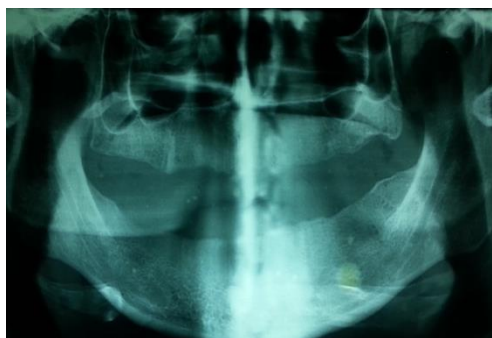
**2.1.1 Identification and Clinical Examination:** Patient A.J., 43 years old, came to the consultation for an esthetic prosthetic rehabilitation of the completely edentulous. The exobuccal examination showed a slight sagging of the upper lip, without altering the height of the lower stage (Figure 1). Clinical examination revealed vertically hypertrophied ridges in the maxilla, especially in the straight premolar-molar regions. This made the prosthetic space insufficient. The right tuberosity is voluminous with a significant vestibular undercut, and the fibromucosa is firm and adherent in the deep planes. There is also a retromolar trigone tuberosity contact (Figure 2 a and b). The panoramic radiograph shows no abnormalities, it allows to make the differential diagnosis with an intra osseous lesion or a tooth included (Figure 3).



**Figure 1:** exo-oral view.



**Figure 2a, b:** endo-oral view.

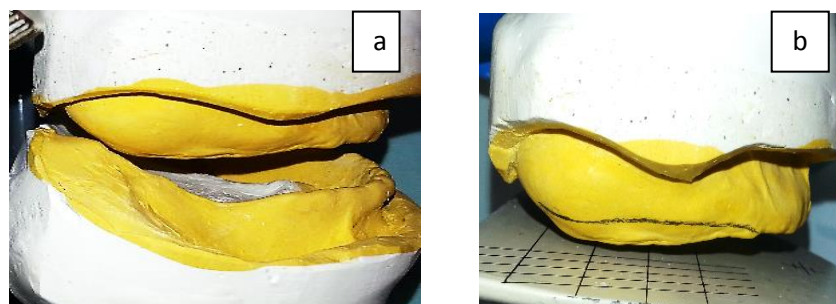


**Figure 3:** Panoramic X-ray.

### 2.1.2 Pre-prosthetic study

A rigorous pre-prosthetic analysis of the clinical case, taking into consideration the various parameters, in particular the esthetics and the occlusion plan within the correct vertical dimension of occlusion (VDO), makes it possible to properly quantify the bone exeresis and to evaluate the necessary surgical corrections that should not be carried out incidentally [3].

The mounting of the study casts to an articulator confirmed a significant hypertrophy of the right maxillary crest in the vertical direction, and thus an insufficient prosthetic space in height (Figure 4 a, b).



**Figure 4 a, b:** the mounting of the study casts on articulator.

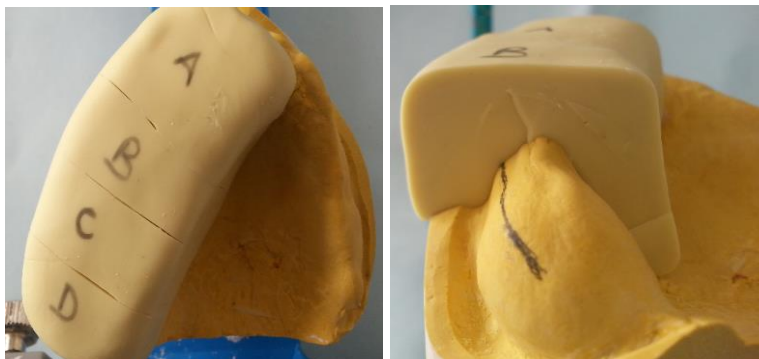### 2.1.3 Therapeutic approach

After studying the case, a subtractive corrective surgery of the right maxillary crest is necessary in order to arrange the reduced prosthetic space and create an inter-arch dimension compatible with the prosthetic realization.

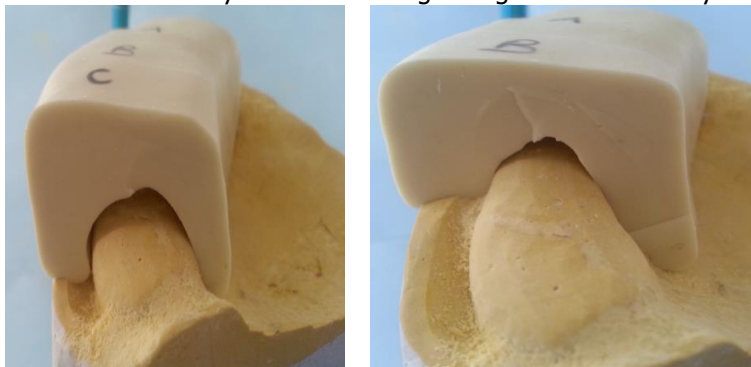
### 2.1.4 Clinical Steps

Surgery must not be mutilating, that is why we have made a silicone key on the primary maxillary model to have a precise idea of the extent and quantity of tissue to be removed. We then cut this key into four parts (Figure 5a and b). Afterwards, the model was corrected by reducing the straight ridge with a plaster knife until a prosthetic space compatible with a correct prosthetic design was created (Figure 6 a and b).

On the corrected model, a transparent resin guide has been made, which will guide the surgery and monitoring of the osteoplasty by transferring to the mouth the corrections made on the model, at the different parts of the ridge.

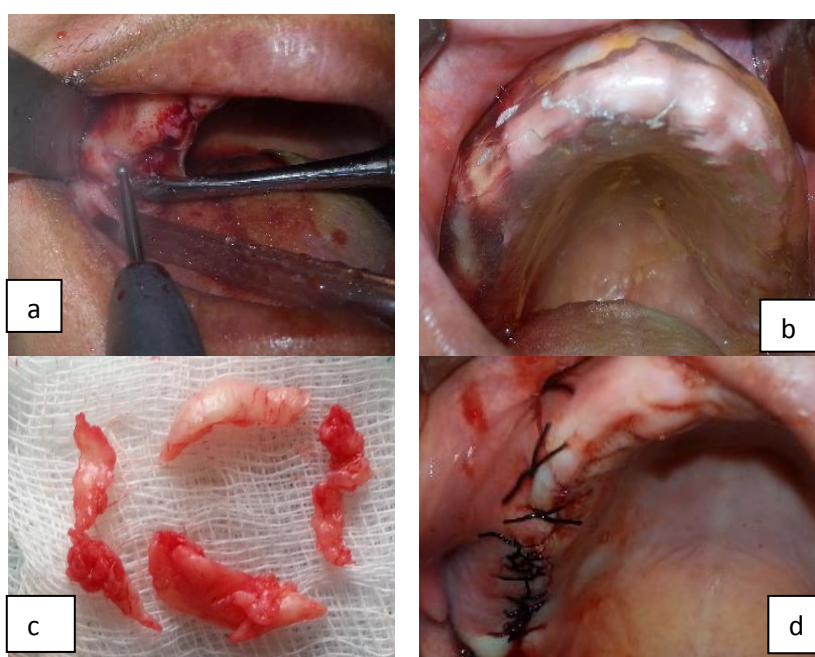


**figure 5:** A silicone key made on the right ridge of the maxillary model.



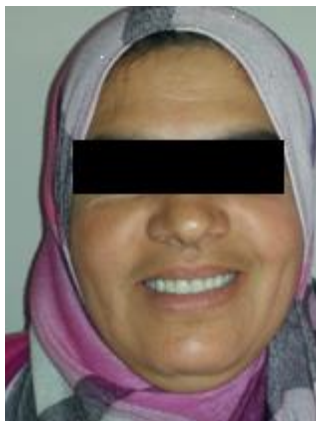**Figure 6:** visualization of the reduced volume using the silicone key after model correction.

The pre-prosthetic surgery for this case consisted of osteoplasty in the vertical and horizontal direction in the right tuberosity, and a thinning of the fibro-mucosa. Bone resection is checked with the surgical guide as it is performed (Figure 7 a,b,c,d)



**Figure 7:** corrective surgery guided by the surgical guide: osteoplasty and Thinning of the fibro-mucosa: **a:** osteoplasty using a burr mounted on a hand piece; **b:** osteoplasty control using the surgical guide; **c:** the fibromucosa in excess; **d:** hermetic sutures.

After healing, the inter-arch prosthetic space was well arranged. The conventional complete removable prosthesis was fabricated in strict respect of the clinical steps. The patient was very satisfied with the esthetic result (figure 8).

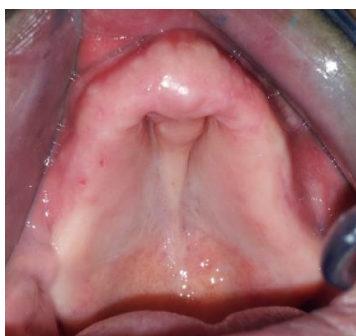

**Figure 8:** Patient satisfaction smile.

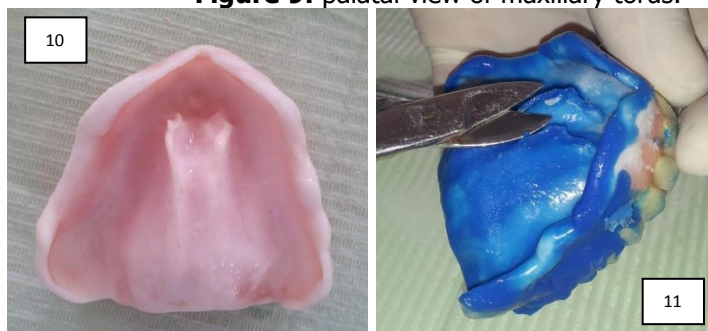## 2.2 Second clinical case

This is a case of rehabilitated total edentulism, in which the maxillary arch presents a deep palate with a small torus (figure 9). The patient complains of pain in the torus and instability of the prosthesis.

basic reflection with relining resin (Kerr FITT), and a discharge of the intrados of the denture has permitted to answer the request from the patient (figures 10,11).



**Figure 9:** palatal view of maxillary torus.



**Figures 10, 11:** Discharged maxillary prosthesis at the level of the torus palatinus

## 3. DISCUSSION

Pre-prosthetic surgery is always part of a comprehensive treatment plan. When the indication is given, certain rules must always be respected regardless of the type of intervention.

The surgical act must be [8]:

- Preceded by a carefully conducted clinical examination.
- Saving on the tissue level
- Supplemented by non-compressive stitches.
- All irregularities and painless reliefs are to be preserved. They will indeed constitute an additional means to improve the hold of the complete prostheses especially in the mandible.
- A post-operative medication will always be prescribed.

And finally, to optimize the post-surgical result, it is crucial not to stop at the simple surgical gesture but to be able to take care of the patient until the beginning of the definitive prosthetic phase. Healing management and temporization are

therefore also necessary for the success of the treatment, thanks to a good tissue conditioning, guiding the remodeling of the osteo-mucosal tissues after surgery. The transitional prosthesis is filled with a delayed-setting resin and placed in the mouth under occlusal pressure. During the temporization phase, the conditioner is regularly renewed until a stable and well-healed bone base is achieved [10].

In this paper, we have focused on the surgery of the bone ridges hypertrophied and the tori. These abnormalities have been the subject of several studies, mainly those of anthropology or epidemiology, which have shown a great difference in prevalence and distribution between the different studies depending on the population and the type of hypertrophy studied [11, 12, 13].

The exact etiology of these bone excrescences is still unclear today. According to studies, the most probable etiology is multifactorial, combining genetic and environmental factors [14, 15, 16]. These bone hypertrophies are often asymptomatic, surgical removal is only justified when they constitute a real obstacle to prosthetic rehabilitation or if functional discomfort occurs (dysphagia, difficulty with oral hygiene and halitosis, sleep apnea in case of lingual space limitation...). Several other authors have also justified the surgical removal of tori, to use it as a source of autogenous bone for implant or periodontal surgery [16, 17]. If there is a contraindication for surgery in the edentulous patient, it is possible to opt for a discharged prosthesis that bypasses the bony prominences. Other authors have suggested the addition of soft acrylic resin to the edges of the prosthesis in a case of mandibular torus in a totally toothless patient. [18]

## 4. CONCLUSION

The presence of bone hyperostoses at the prosthesis bearing surfaces may compromise the prosthetic rehabilitation, which may require a surgical arrangement of the prosthetic space after a careful assessment of the clinical case.

## 5. REFERENCES:

1. Castany E., Laffargue P., et Godet C. Aménagement pré-prothétique des crêtes édentées: six situations cliniques fréquentes. *Inf Dent.* 2002 ; 38: 2868-2874.
2. Regragui A., Sefrioui A., Merzouk N., Berrada S. Hypertrophie osseuse buccale chez l'édenté complet : une fatalité à contourner. *Actual Odonto-Stomatol.* 2016 ; (275).
3. Fadwa Guessous Doss. Hypertrophie osseuse et réhabilitation prothétique par prothèse amovible complète immédiate d'usage. *Stratégie Prothétique.* 2017 ; (1) : 16-19.
4. Martin-Duverneuil N., Auriol M. Les tumeurs maxillo-faciales. *Sauramps médical.* 2004 ;402 p. (Imagerie-Anatomopathologie).
5. Garcia-Garcia AS., Martínez-González J-M., Gómez-Font R., Soto-Rivadeneira A., Oviedo-Roldán L. Current status of the torus palatinus and torus mandibularis. *Med Oral Patol Oral Cir Bucal.* mars 2010;15(2): e353-360.
6. Hascoet.E., Vaillant PY., Tempescul A., Darbin.C., Lansonneur.C, Boisramé.S Cas clinique et revue de littérature, Tori et exostoses multiples : présentation d'un cas et revue de la littérature. *Med Buccale Chir Buccale* 2015; 21:19-24.
7. Horning GM., Cohen ME., Neils TA: Buccal alveolar exostoses: prevalence, characteristics, and evidence for buttressing bone. *J Periodontol* 2000; 71 (6): 1032-42.
8. Medsinge SV., Kohad R., Budhiraja H., Singh A., Gurha S., Sharma A. Buccal exostosis: a rare entity. *J Int Oral Health.* 2015;7(5): 62-4.
9. Hauteville A., Cohen A.S., Manuel d'odontologie chirurgicale. *Paris : Masson ;* 1989. Chapitre 9.
10. Bagui M., Fajri I., El mohtarime B., Merzouk N. La place de la mise en condition tissulaire en prothèse adjointe totale. *Actual Odonto-Stomatol.* 2016; (275).
11. Antoniadis DZ., Belazi M., Papanayioutou P. Concurrence of torus palatinus with palatal and buccal exostoses. Case report and review of the literature. *Oral Surg Oral Med Oral Pathol Oral Radiol Endod.* 1998; 85: 552.
12. Haugen LK., Palatine and mandibular tori. A morphologic study in the current Norwegian population. *Acta Odontol Scand.* 1992; 50(2): 65-77.
13. Aree J et al. Buccal and palatal exostoses: prevalence and concurrence with tori. *Oral Surgery Oral Medicine Oral Pathology.* 2000; 90 (1): 48-53.
14. Khan S., Shah SAH., Ali F., Rasheed D. Concurrence of Torus Palatinus, Torus Mandibularis and Buccal Exostosis. *J Coll Physicians Surg Pak.* 2016 Nov; 26(11):111-113. doi: 217.
15. Oualalou Y.Azaroual M.F. Zaoui F.Chbicheb S. Berrada S.Prévalence et caractéristiques cliniques des hypertrophies osseuses buccales dans une population marocaine Prevalence and clinical characteristics of oral bony outgrowth in a Moroccan population. *Revue de Stomatologie, de Chirurgie Maxillo-faciale et de Chirurgie Orale.* 2014; 115(5.) : 268-273.
16. Smithaa.k., Smitha G.P. Alveolar exostosis – revisited: A narrative reviewof the literature.*The Saudi Journal for Dental Research.* February 2014.
17. Santhanakrishnan M., Rangarao S., Mandibular Tori. A source of autogenous bone graft. *J Indian Soc Periodontol.* 2014; 18(6): 767-71. doi: 10.4103/0972-124X.147423
18. Abrams S. Complete denture covering mandibular tori using three base materials: a case report. *J Can Dent Assoc.* 2000; 66(9): 494-6.



**Cite this article: Kanza Mrhar, Yasmina Cheikh, Khadija El assraoui, and Samira Bellemkhannate. BONE HYPERTROPHIES IN EDENTULOUS PATIENTS: FROM DIAGNOSIS TO PROSTHETIC REHABILITATION). *Am. J. innov. res. appl. sci.* 2020; 11(3): 214-218.**

This is an Open Access article distributed in accordance with the Creative Commons Attribution Non Commercial (CC BY-NC 4.0) license, which permits others to distribute, remix, adapt, build upon this work non-commercially, and license their derivative works on different terms, provided the original work is properly cited and the use is non-commercial. See: <http://creativecommons.org/licenses/by-nc/4.0/>